

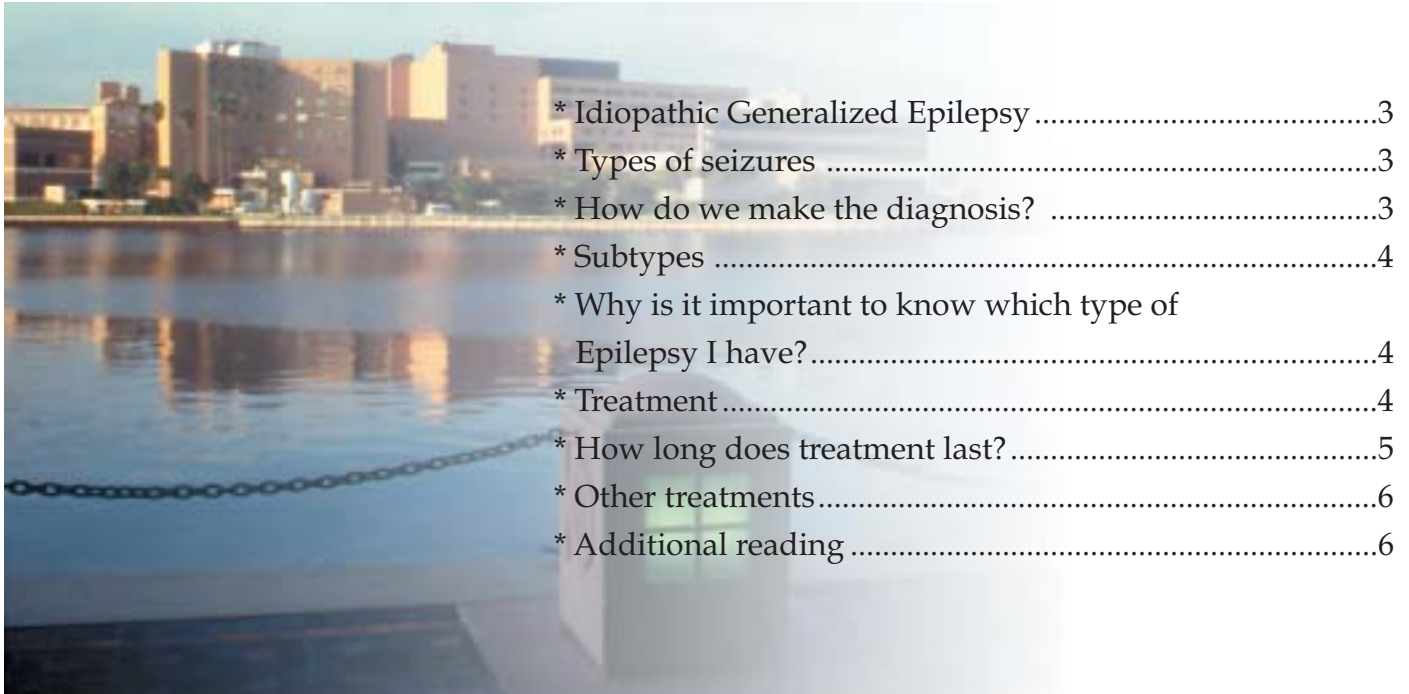
Idiopathic ("Primary") Generalized Epilepsy

Selim R. Benbadis, MD
Leanne Heriaud, RN

Comprehensive Epilepsy
Program



Table of Contents



* Idiopathic Generalized Epilepsy	3
* Types of seizures	3
* How do we make the diagnosis?	3
* Subtypes	4
* Why is it important to know which type of Epilepsy I have?	4
* Treatment	4
* How long does treatment last?	5
* Other treatments	6
* Additional reading	6

Comprehensive Epilepsy Program

◆ **Selim R. Benbadis, MD**
Associate Professor
Department of Neurology & Neurosurgery
Director, Comprehensive Epilepsy Program and
Clinical Neurophysiology Laboratory
University of South Florida &
Tampa General Hospital
(813) 259-0605
sbenbadi@hsc.usf.edu
<http://epilepsy.usf.edu>

◆ **Leanne Heriaud, RN, BSN**
Coordinator, Comprehensive Epilepsy Program
Tampa General Hospital
(813) 844-4675
lheriaud@tgh.org



Understanding Seizures & Epilepsy

IDIOPATHIC GENERALIZED EPILEPSY

Idiopathic generalized epilepsy, abbreviated IGE, is a group of epilepsy that has very distinct features. It is also called “primary” generalized epilepsy. The term “idiopathic” is misleading, because it usually means “cause unknown,” which is not true here.

Idiopathic generalized epilepsies have the following characteristics:

- They are *genetic* and not caused by any brain physical abnormality. This means that the brain is anatomically normal.
- They basically represent a *genetic low threshold (or high susceptibility) for seizures*.
- Thus, there is often, but not always, a family history of epilepsy. (If everyone had 50 siblings, patients with IGE would more often have a family member affected).
- For some specific types (for example, juvenile myoclonic epilepsy) the chromosome and gene have even been identified. Others will almost certainly be identified.
- They tend to begin during childhood or adolescence, although they may not be *diagnosed* until adulthood.
- People with IGE have normal intelligence, normal neurological examination, and normal MRIs.
- Although they are clearly genetic, they are not transmitted predictably like, for example, hemophilia or cystic fibrosis.

TYPES OF SEIZURES

Type of seizures

- Patients with IGE have one or more of 3 types of (primary generalized) seizures: myoclonic, absence and generalized tonic-clonic seizures.
- One type may be the only or main type in a given patient.
- Generalized tonic-clonic seizures are convulsions of the whole body lasting 1-2 minutes, and are the most common and most dramatic type of seizures.
- Absence seizures are brief staring spells with arrest of activity, often with eye fluttering, which last just a few seconds.
- Myoclonic seizures are very brief isolated body jerks that tend to occur in the morning.



Understanding Seizures & Epilepsy

HOW DO WE MAKE THE DIAGNOSIS?

How do we make the diagnosis?

- It may be difficult, and at times impossible, to make a precise diagnosis of epilepsy type (beyond just “epilepsy” or “seizure disorder”).
- Age of onset is usually early in life.
- The types of seizures seen in IGE are described above.
- Intellectual functions, neurological exam, and imaging (MRI) are normal in IGE.
- The **electroencephalogram (EEG)** is the only definitive test to confirm the diagnosis of IGE. Unfortunately, a single EEG is often normal in patients with epilepsy, in which case it does not help. When abnormal, the EEG in IGE is very characteristic, with various combinations of generalized spike-wave complexes, spikes, or polyspikes, sometimes triggered by flashing lights (photosensitivity) (see figures).

SUBTYPES OF IGE

Subtypes of IGE

Depending on age at onset, predominant seizure type(s), and EEG findings, several subtypes of IGE exist:

- Childhood absence epilepsy: typically begins between 4 and 10 years of age. The main seizure type is typical absences, which are brief (about 10 seconds), but occur frequently (usually >10 daily). About 50% of patients also have generalized tonic clonic seizures, and very few also have myoclonic seizures. EEG shows very characteristic pattern wave complexes.
- Juvenile myoclonic epilepsy (JME) typically begins in adolescence (12-18 years), and is characterized by myoclonic jerks, particularly in the morning. EEG shows a very characteristic pattern called generalized polyspikes, often with generalized 3 Hz spike-wave complexes.
- Epilepsy with grand-mal seizures consists of generalized tonic clonic seizures mainly, which may be more frequent in the morning. EEG can show either of the above patterns or generalized spikes.

WHY IS IT IMPORTANT TO KNOW WHICH TYPE OF EPILEPSY YOU HAVE?

Why is it Important to know exactly which type of epilepsy you have?

- Because treatment options are not exactly the same for IGE and partial (focal) epilepsies. Some drugs work better than others for this type of epilepsy (see below). Also, surgery is never an option for this type of epilepsy.
- Because prognosis is very different.



Understanding Seizures & Epilepsy

Why is it important to know, continued...

TREATMENT

HOW LONG DOES TREATMENT LAST?

- The IGEs are usually easy to treat, i.e., they respond to medications in about 90% of patients.
- Many IGEs are outgrown in young adulthood, with the exception of JME.
- Many patients with IGE are wrongly diagnosed with “complex partial seizures” (partial epilepsy), which results in a poor choice of medications such as, for example phenytoin (Dilantin), carbamazepine (Tegretol), or gabapentin (Neurontin).

Treatment

- Many drugs are available to treat epilepsy, but they are not all appropriate for this type of epilepsy.
- Phenytoin (Dilantin), carbamazepine (Tegretol), gabapentin (Neurontin), tiagabine (Gabitril), oxcarbazepine (Trileptal) are excellent drugs for partial (focal) seizures, but *do not work well in IGE*. In fact they can make some seizures worse. This is unfortunate because phenytoin (Dilantin) and carbamazepine (Tegretol) are the most often prescribed drugs for seizures in the U.S..
- The classic drug of choice for IGE is valproic acid (Depakote).
- For patients (usually children) with absence seizures only, ethosuximide (Zarontin) is also an option.
- Other medications can be used in IGE. Phenobarbital and primidone (Mysoline) are old drugs that tend to cause sedation. The following drugs may well be an option too, although they are not yet officially approved for this: lamotrigine (Lamictal), topiramate (Topamax), levetiracetam (Keppra), zonisamide (Zonegran).

How long does treatment last?

- With the exception of juvenile myoclonic epilepsy (JME), these are often outgrown (roughly 50% of the time) in young adulthood, so weaning may be tried.
- JME is the only type that is not outgrown, so attempts to stop drugs in JME usually fail.



OTHER TREATMENTS

Other treatments

Non-drug treatments like the ketogenic diet and vagus nerve stimulation are rarely considered in IGE, because response to medications is usually excellent. As mentioned above, epilepsy surgery is never an option for IGE.

ADDITIONAL READING

Additional reading

- Benbadis SR. Observations on the misdiagnosis of generalized epilepsy as partial epilepsy: causes and consequences. *Seizure* 1999;8:140-145.
- Benbadis SR, Lüders HO. Epileptic syndromes: an underutilized concept. *Epilepsia* 1996;37:1029-1034.
- Benbadis SR. Epileptic seizures and syndromes. *Neurologic Clinics* 2001;19:251-270.
- Berkovic S, Benbadis SR. Childhood absence epilepsy and juvenile absence epilepsy. In: Wyllie E (ed). *The treatment of epilepsy: Principles and practice*. 3rd edition. Philadelphia: Lippincott, Williams & Wilkins, 2001, pp. 485-490.
- Lancman ME, Asconapé JJ, Penry JK. Juvenile myoclonic epilepsy: an underdiagnosed syndrome. *J Epilepsy* 1995;8:215-218.
- Reutens DC, Berkovic SF. Idiopathic generalized epilepsy of adolescence: are the syndromes clinically distinct? *Neurology* 1995;45:1469-1476.
- Serratosa JM. Juvenile myoclonic epilepsy. In: Wyllie E (ed). *The treatment of epilepsy: Principles and practice*. 3rd edition. Philadelphia: Lippincott, Williams & Wilkins, 2001, pp. 491-507.